



# Orthodromic temporalis tendon transfer

Garrett R. Griffin, MD<sup>a</sup>, Jennifer C. Kim, MD<sup>b</sup>

From the <sup>a</sup>The Center for Advanced Facial Plastic Surgery, Beverly Hills, California; and

<sup>b</sup>Department of Otolaryngology, University of Michigan Health System, Ann Arbor, Michigan.

## KEYWORDS

Facial paralysis;  
Regional muscle  
transfer;  
Temporalis tendon  
transfer;  
Facial rehabilitation

Chronic facial paralysis is a challenging clinical entity. One of the primary goals is re-establishment of a dynamic smile, which is so important to everyday social interaction. When the facial muscles are denervated for longer than approximately 2 years, they atrophy and fibrose making nerve transfer procedures ineffective. In these cases, regional or free muscle transfer is necessary to achieve dynamic facial movement. Over the past decade, orthodromic temporalis tendon transfer has become a favored facial reanimative procedure. The surgical technique, and important pre- and postoperative factors, are discussed.

© 2012 Elsevier Inc. All rights reserved.

Chronic facial paralysis is a devastating condition with severe functional and emotional consequences. A complete unilateral facial paralysis results in nasal obstruction, oral incompetence, corneal exposure, and most importantly, results in the loss of spontaneous facial expression, which is so integral to human social interaction and communication. Over the past decade, facial plastic and reconstructive surgery has achieved a relative golden age, in which surgeons have an astounding armamentarium of medical, surgical, and technological interventions with which to address the functional and esthetic consequences of facial paralysis. With few exceptions, the reanimative surgeon is now able to protect the eye, improve oral incompetence, and achieve static symmetry.

However, reliable dynamic facial movement remains a challenge. Dynamic facial motion requires stimulatory input to functioning musculature. Options for input include the native nerve when available, the contralateral intact facial nerve via cross-facial nerve grafts, or various ipsilateral motor nerves, including the hypoglossal and masseteric nerves. Chronic denervation leads to facial muscle atrophy. After a critical period, generally believed to be 18-24 months, reinnervation of these atrophic muscles is unlikely to restore facial movement. In the absence of functional

native facial musculature, regional or free muscle transfer is required.

Most muscle transfers to the face are targeted to the corner of the mouth to re-create a recognizable pleasing smile. The masticators represent a group of powerful muscles located close to the mouth that are innervated by the mandibular division of the trigeminal nerve, thus preserving them in facial paralysis. Both the masseter and temporalis muscles have been used for dynamic smile restoration. Initially, the temporalis was used in an antidromic manner by freeing a portion of muscle belly from the temporal fossa and transposing it over the superior and lateral zygomatic arch before suturing it to the region of the modiolus. This created a “double-contour” deformity with a depression in the temporal fossa and a bulge over the arch, causing it to fall out of favor. In recent years, orthodromic temporalis tendon transfer has become the favored regional muscle technique.

## Pertinent anatomy

The temporalis muscle is a skeletal muscle that originates from the temporal fossa, the deep surface of the superficial layer of the deep temporal fascia, and the greater wing of the sphenoid. The muscle is classically described as inserting on the mandibular coronoid, but the tendon attaches to a significant portion of the mandible. It covers the top and lateral

**Address reprint requests and correspondence:** Garrett R. Griffin, MD, The Center for Advanced Facial Plastic Surgery, Beverly Hills, CA.  
E-mail address: [griffin.fpsurgery@gmail.com](mailto:griffin.fpsurgery@gmail.com)

aspects of the coronoid, and then wraps around the anterior ramus to cover much of the medial ramus, posteriorly as far as the third molar. If completely and carefully removed from the mandible, the tendon measures 4-6 cm in width at its inferior end. Tracing the tendon superiorly reveals that it fans out to become a tough fibrous lamina. The distance from the coronoid's native location to the modiolus is approximately 4 cm.<sup>1</sup> The temporalis muscle is innervated by the anterior and posterior deep temporal nerves from the anterior division of the mandibular nerve (CN V<sub>3</sub>). The muscle is supplied by the deep temporal arteries, which arise from the middle third of the internal maxillary artery and course superiorly between the muscle and skull before entering the muscle itself. There is a glide plane between the temporalis muscle and zygomatic arch. The infratemporal fossa contains largely fatty tissue, including the buccal fat pad. The tendon can move freely in this space even after transfer. The coronoid is often approached through an incision in the melolabial crease, with passage through the buccal space. The plane of dissection is between the masseter muscle laterally and buccinator muscle medially. The parotid duct and buccal fat pad are the anatomic structures in this region.

## Surgical techniques

Orthodromic temporalis tendon transfer was first described by McLaughlin<sup>2</sup> in 1953. In his original report, he identified several transcutaneous and transoral approaches to the coronoid process. Once the coronoid was reached, he drilled a hole in it, and separated it from the rest of the mandible by cutting from the anterior edge of the ramus back into the mandibular notch. He emphasized that the coronoid should be grasped with something (he used a wire through the drill hole) before releasing it, as it will retract up into the infratemporal fossa and may be difficult to retrieve. McLaughlin then passed a free tensor fascia lata (TFL) strip through the drill hole and used it to loop around a second TFL strip that had been passed into the upper and lower lips just past the midline. Several modifications of this original technique are reported. There are variations in managing the muscle origin in the temporal fossa, in surgical access to the mandibular condyle and temporalis tendon, and in the method of connection to the corner of the mouth.

Labbé<sup>3</sup> has reported the most unique approach, which he has termed lengthening temporalis myoplasty. His technique grew out of the philosophy that the temporalis muscle action should be kept as natural as possible, with maximum tendon preservation and no interposition graft between the tendon and mouth. It is possible to simply free the tendon from the coronoid and suture it to the melolabial region, but this puts the muscle under significant stretch. This could result in a disadvantageous point on the length-tension curve, where there is little overlap between actin and myosin chains, few cross-bridges, and minimal force generated. Excess tension may also over-

elevate the oral commissure. Labbé's solution is to release the muscle from the temporal fossa by dividing it 1 cm inferior to the temporal line (which leaves a thick strip along the temporal line for reattachment at the end of the case). This is accomplished through a hemicoronal incision. The coronoid is also approached through this incision by dividing the zygomatic arch anterior and posterior to the masseteric insertion, allowing it to be moved inferiorly out of the way. The coronoid is then divided, keeping as much tendon attached to the separated bone as possible. A 4-cm incision is made in the melolabial crease, and a tunnel is dissected between the masseter laterally and buccal fat pad medially, until the coronoid can be grasped and pulled through the melolabial incision into the face. At this point, the tendon can be carefully dissected off the bone, and the bone discarded. The tendon is then attached to the facial musculature at the desired anchor points using nonabsorbable suture. The temporalis muscle is reattached to the preserved fascial strip at the temporal line using nonabsorbable suture. Enough tension should be placed on these sutures such that the corner of the mouth is slightly overcorrected. There should remain a small gap between the muscle and the superior fascial strip. Labbé routinely allows the muscle belly to slide anteriorly such that the posterior temporal fossa is not re-covered with muscle. As discussed earlier in the text, cadaver studies have shown that the tendon is moved inferiorly 4 cm to reach the melolabial region; thus, the goal when reattaching the temporalis muscle belly is to provide 3-4 cm of release. Published results are good to excellent, with as much as 15 mm of excursion achieved. This rivals the best results with free gracilis transfer.

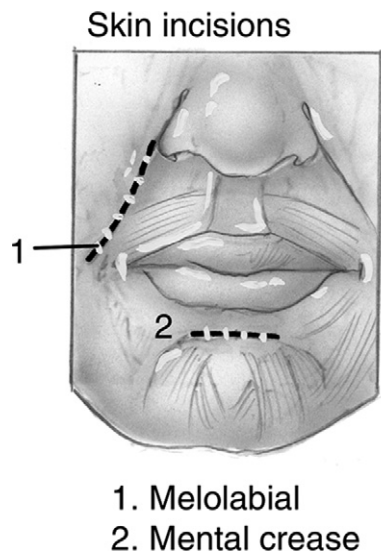
The authors have used Labbé's technique and have been unable to achieve the same impressive results. Compared with our current technique described later in the text, it is a relatively long invasive surgery that adapts an infratemporal skull base approach to facial paralysis. An endoscopic modification of Labbé's technique has been reported, which eliminates the hemicoronal incision, but the surgical time and invasiveness is unchanged.<sup>4</sup> Byrne et al<sup>5</sup> start by initially transferring the tendon to the melolabial fold without a fascial extension graft. They then evaluate the stretch on the muscle, and release the posterior aspect of the temporalis (like Labbé) only if necessary. In 7 patients, excursion ranged from 1.6 to 8.5 mm (mean, 4.2 mm). Patients had high levels of subjective satisfaction as reported on an unvalidated questionnaire.

## Author's technique

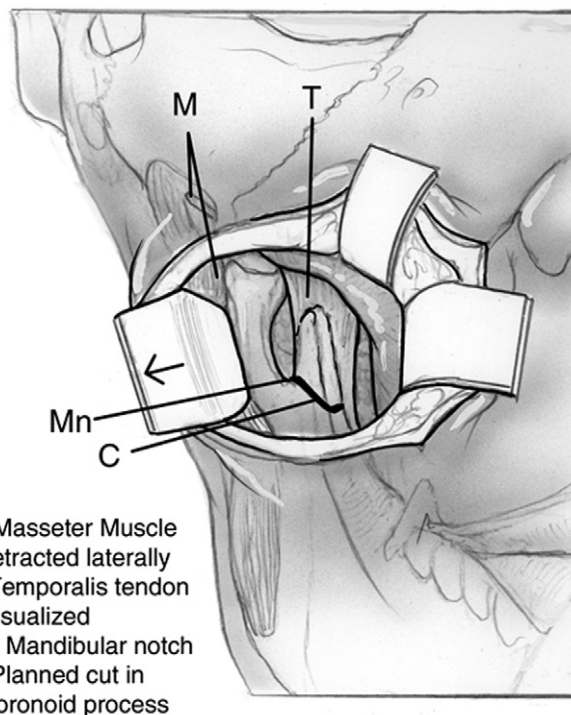
The authors currently use a technique similar to McLaughlin's original description. In the preoperative holding area, the melolabial crease on the paralyzed side is identified and marked out. The procedure is begun by harvesting a large piece of tensor fascia lata, at least

10 × 5 cm<sup>2</sup>. The majority of the procedure is completed through an incision in the melolabial crease that extends from the nasal alar base down to the level of the oral commissure (Figure 1). Blunt finger dissection is performed to palpate and then expose the anterior border of the masseter muscle. Often, the anterior border of the masseter is detached from the zygomatic arch for 1 or 2 cm to improve exposure. Opening and closing the mouth moves the coronoid and aids in identification. The anterior face and medial face of the ramus are then exposed, allowing visualization of the mandibular notch and temporalis tendon insertion. Lighted retractors are excellent to maintain exposure during this dissection, and protect the surrounding tissues while an oscillating saw is used to separate the coronoid from the rest of the mandible (Figure 2). The coronoid is grasped with an Allis forceps or hemostat before completing separation to prevent retraction once released. We do not routinely identify the parotid duct, although it is theoretically at risk. Some groups specifically identify and ligate the parotid duct to limit the risk of infection.<sup>6</sup> We have had no serious infections in patients who have not received radiation therapy.

Attention is then turned to attaching the TFL graft to the mouth. We typically cut the graft as depicted in Figure 3 such that it can be sewn to the midline lower lip and along the melolabial fold. A 15-mm incision is made in the midline mental crease and carried down to the facial musculature. A tenotomy scissors is used to dissect a tunnel from this point laterally along the lower lip to connect to the melolabial incision. One must be careful not to violate the oral mucosa during this maneuver. A hemostat is passed through this tunnel and used to grasp the TFL graft and pull it into the lower lip (Figure 3). The graft is sewn to the midline lower-lip musculature using 4-0 PDS (Figure 4). The upper portion of the TFL graft is sewn to the facial



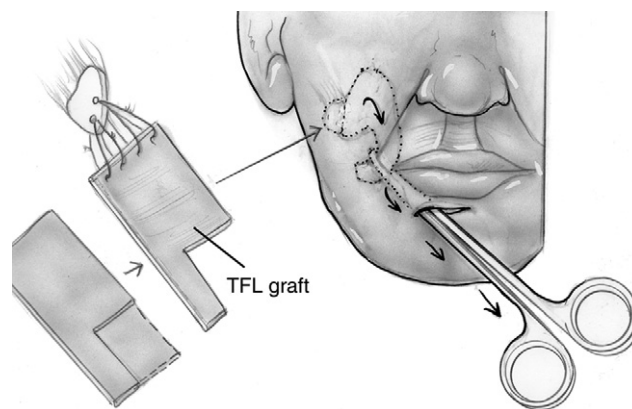
**Figure 1** Facial incisions for orthodromic temporalis tendon transfer. The melolabial incision is from the level of the ala to the level of the oral commissure. The mental crease incision is centered on the midline and is approximately 15 mm in length.



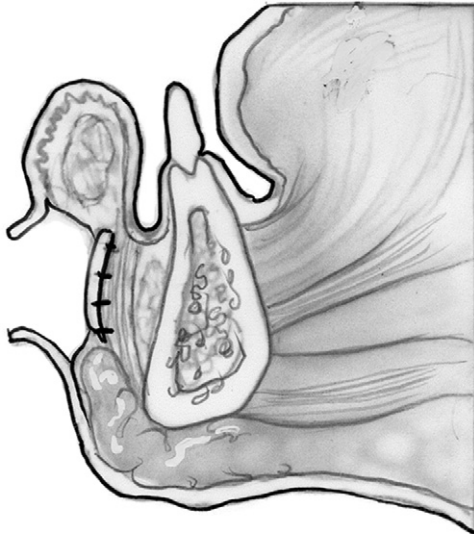
**M- Masseter Muscle retracted laterally**  
**T- Temporalis tendon visualized**  
**Mn- Mandibular notch**  
**C- Planned cut in coronoid process**

**Figure 2** Transfacial approach to the coronoid. After incision, blunt dissection through the facial and buccal fat lateral to the buccinator will identify the masseter. The masseter is retracted laterally to identify the coronoid.

musculature at multiple points just medial to the melolabial incision such that when tension is exerted, a symmetric melolabial fold is created. The lateral extent of the TFL is trimmed such that attaching it to the coronoid will result in slight overcorrection. We use a wire-passer drill to make 2 or 3 small holes in the coronoid. To complete the suspension, 3-0 PDS suture is then passed through these holes and the coronoid is sutured to the TFL. Melolabial and lower-lip incisions are closed using deep 5-0 poliglecaprone



**Figure 3** The rectangular fascia is cut as demonstrated. It is then attached to the coronoid with suture through holes drilled in the coronoid. Once tied down, the lateral aspect of the fascia bunches up, creating the final appearance seen in Figure 6. A hemostat is used to pull the fascial graft from the face into the lower lip through the tunnel that has been created.



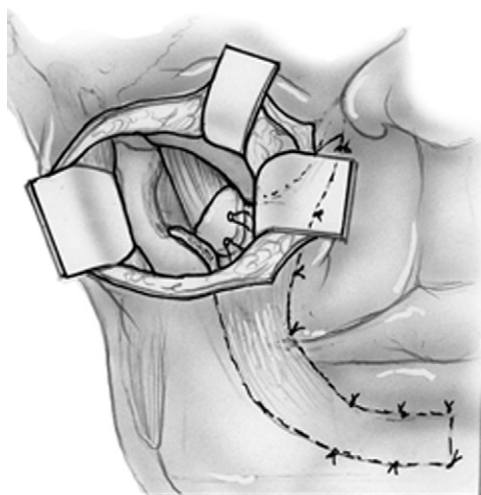
**Figure 4** The fascial graft is sewn down to the facial musculature in the midline mental crease. The skin is then sutured over the fascial graft in 2 layers.

(Monocryl, Ethicon, San Angelo, TX) and superficial 5-0 fast gut or 6-0 nylon sutures (Figures 5 and 6).

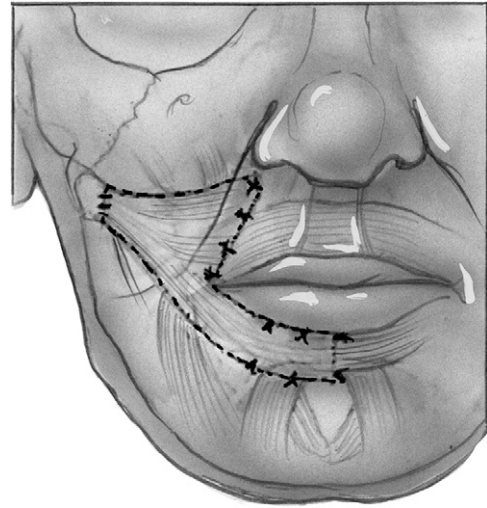
### Preoperative evaluation

For TTT to be successful, a healthy innervated temporalis muscle is required. Any history of surgery in the temporal fossa should be evaluated. Cranial nerve V3 injury will compromise the innervation to the muscle and should be considered, particularly in patients who have undergone skull base surgery. The surgeon should ask the patient to bite down while palpating over the temporal fossa to ensure the muscle fires effectively.

In general, our patients with a history of radiation therapy to the parotid bed have done poorly after TTT. We found significantly decreased commissure movement com-



**Figure 5** The coronoid has been separated from the mandible and connects the fascial graft to the temporalis muscle.



**Figure 6** Completed temporalis tendon transfer with the fascial extension graft sutured to the coronoid, midline lower lip, and just medial to the melolabial crease.

pared with patients with no previous history of radiation therapy. Of 7 patients, 2 developed wound infections that required parenteral antibiotics and ultimately removal of the tensor fascia lata graft. The patients who received radiation therapy did still achieve good static symmetry (in publication).<sup>7</sup> We would recommend trying to avoid placing any free fascial tissue in patients who have received radiation, as it can serve as a nidus for infection. This may require partial release of the temporalis muscle from the temporal fossa as discussed earlier in the text.

### Intraoperative factors

We typically perform our TTT using oral intubation. To minimize distortion of the lips, and to keep tape off the face, we attach the endotracheal tube to the central maxillary incisors using circumdental heavy silk sutures. Some groups prefer transnasal intubation for TTT, arguing that it allows a better assessment of smile symmetry during attachment of the tendon. Labbé has reported intraoperative electrical stimulation of the temporalis.<sup>8</sup> This enables one to ensure that the muscle is firmly sutured into place, and to fine-tune the insertion point to maximize smile symmetry. This is an interesting concept that deserves further investigation. If intraoperative electrical stimulation is planned, the patient cannot be given long-acting paralytics.

### Postoperative care

Aggressive postoperative physiotherapy is essential to optimize outcomes after TTT. Initially, patients focus on re-learning to fire the temporalis while biting down. Once this is mastered, patients will need to work on consciously biting down while smiling to move both sides of the mouth.

Practicing in front of a mirror and biofeedback devices are helpful.<sup>9</sup> Eventually, cortical reorganization may occur in which the motor cortex dedicated to the temporalis muscle becomes reprogrammed to fire unconsciously during smile.<sup>10</sup> It can be hard to find a physiotherapist to oversee rehabilitation. At some institutions, this will be a physical therapist, whereas at others, it might be an occupational therapist.

Because the temporalis muscle is living vascular tissue, successful TTT does not typically require revision over time like a static suspension does. That said, the lips on the paralyzed side elongate in facial paralysis, creating asymmetry even if the TTT itself is perfect. In these cases, small adjunct procedures like vermilionectomy or wedge excision of the lip may be necessary to create more perfect resting and active symmetry.

## Conclusions

Temporalis tendon transfer has become the regional muscle transfer of choice for reanimating the smile in chronic facial paralysis. Within a common theme, there are numerous variations on how to harvest and attach the tendon to the corner of the mouth.<sup>7</sup> Careful perioperative planning and aggressive postoperative rehabilitation are critical to optimize results. When this is done, up to 15 mm (average, 3-5 mm) of commissure excursion can be produced.

## References

1. Bénateau H, Alix T, Labbé D, et al: Anatomic study of the tendinous insertion lamina of the temporalis muscle. *Surg Radiol Anat* 26:281-284, 2004
2. McLaughlin CR: Surgical support in permanent facial paralysis. *Plast Reconstr Surg* (1946) 11:302-314, 1953
3. Labbé D, Huault M: Lengthening temporalis myoplasty and lip reanimation. *Plast Reconstr Surg* 105:1289-1297, 2000
4. Contreras-García R, Martins PD, Braga-Silva J: Endoscopic approach for lengthening the temporalis muscle. *Plast Reconstr Surg* 112:192-198, 2003
5. Byrne PJ, Kim M, Boahene K, et al: Temporalis tendon transfer as part of a comprehensive approach to facial reanimation. *Arch Facial Plast Surg* 9:234-241, 2007
6. Sidle DM, Fishman AJ: Modification of the orthodromic temporalis tendon transfer technique for reanimation of the paralyzed face. *Otolaryngol Head Neck Surg* 145:18-23, 2011
7. Griffin GR, Abuzeid W, Vainshtein J, et al: Outcomes following temporalis tendon transfer in irradiated patients. *Arch Facial Plast Surg* (in press).
8. Har-Shai Y, Gil T, Metanes I, et al: Intraoperative muscle electrical stimulation for accurate positioning of the temporalis muscle tendon during dynamic, one-stage lengthening temporalis myoplasty for facial and lip reanimation. *Plast Reconstr Surg* 126:118-125, 2010
9. Pereira LM, Obara K, Dias JM, et al: Facial exercise therapy for facial palsy: systematic review and meta-analysis. *Clin Rehabil* 25:649-658, 2011
10. Har-Shai Y, Metanes I, Badarny S, et al: Lengthening temporalis myoplasty for facial palsy reanimation. *Isr Med Assoc J* 9:123-124, 2007