

Outcomes Following V-Y Advancement Flap Reconstruction of Large Upper Lip Defects

Garrett R. Griffin, MD; Stephen Weber, MD, PhD; Shan R. Baker, MD

Objective: To characterize revision surgery following V-Y subcutaneous tissue pedicle advancement flap repair of large upper lip skin defects.

Methods: Retrospective review of upper lip skin defects at least 3.0 cm² in area that were reconstructed with a V-Y subcutaneous tissue pedicle advancement flap at an academic tertiary care center. Depth and area of the defect, as well as involvement of the vermilion and nasal ala, were recorded as independent variables. Revision techniques were analyzed to identify patterns.

Results: Thirty patients were identified as having upper lip skin defects with a mean (range) area of 7.0 (3.0-14.0) cm² (median, 6.25 cm²). The defect involved the

nasal ala in 4 cases and the vermilion in 3 cases. At least 1 revision surgery was performed in 14 patients (47%). Alar or vermilion involvement was a significant factor in revision by χ^2 analysis ($P=.03$). Larger defect size did not predict a need for revision, even among cases where the defect did not involve the ala or vermilion ($P=.68$).

Conclusions: Reconstruction of large upper lip skin defects with a V-Y subcutaneous tissue pedicle advancement flap is associated with a 47% revision rate, and when the defect involves the ala or vermilion, the revision rate is increased. Defect size alone cannot be used to predict the need for revision surgery. Revision techniques are demonstrated.

Arch Facial Plast Surg. 2012;14(3):193-197

THE UPPER LIP IS A FUNCTIONALLY and aesthetically important region of the face. Broadly, it comprises cutaneous and vermilion components that are separated by the vermiliocutaneous junction. The cutaneous portion is further divided into 2 paired lateral subunits bounded by the nasal base and melolabial folds and separated by the midline philtrum. The intersection of the philtrum with the red lip creates the delicate "cupid's bow."¹

The upper lip is also a relatively frequent site of cutaneous malignancy. Surgical excision is the treatment of choice for most skin cancers of the lip. The technique used to reconstruct the resulting surgical defect depends on location, size, depth, and adjacent subunit involvement. Reconstruction of small (<1 cm) cutaneous defects of the upper lip can be achieved with lip advancement (primary) closure if located in the middle to lower lip, but this might require excising a standing cutaneous deformity of the red lip. Full-thickness skin grafting can always be used for repair of superficial skin defects of the upper lip, regardless of size. This can result in a poor color match between the graft and adjacent lip skin or in a contour depression. Larger cutaneous de-

fects can be converted to full thickness and repaired with lip advancement if perfectly midline or with full-thickness lip switch flaps from the lower lip. However, the latter is a complex surgical option requiring creation of scars in the lower lip and interval pedicle detachment requiring another surgical procedure. The local flaps that can be used in the upper lip are limited because they often distort the nose, vermiliocutaneous junction, melolabial crease, or philtral columns.

A V-Y advancement flap of adjacent upper lip skin based on a subcutaneous tissue pedicle is an excellent technique for reconstructing lateral, skin-only upper lip defects larger than 1 cm². This method places scars along aesthetic borders and advances skin of similar characteristics into the upper lip. Furthermore, this method maintains oral sphincter competence and facial nerve function. Given the robust subcutaneous pedicle, this flap is a reliable option for upper lip reconstruction in most patients, including smokers. Subcutaneous undermining of portions of the flap allows advancement of a skin flap of similar thickness and contour into the upper lip. Mobilizing the island flap solely on the subcutaneous fat adjacent to the modiolus enables advancement of the flap up to and slightly beyond the philtrum, allow-

Author Affiliations:
Department of Otolaryngology–Head and Neck Surgery, University of Michigan Health System, Ann Arbor (Drs Griffin and Baker); and Lone Tree Facial Plastic & Cosmetic Surgery Center, Lone Tree, Colorado (Dr Weber).

ing reconstruction of skin defects as large as one-half of the upper lip.

In 1998, our group published our technique and the largest series of V-Y subcutaneous tissue pedicle advancement flaps used for upper lip reconstruction in the literature to date.² In that report, 35% of defects at least 4 cm² in area required flap contouring (“debulking”), although this statistic included defects with a significant cheek component. The purpose of this study was to further analyze larger upper lip skin defects repaired with this method in an effort to identify defect characteristics that might predict the need for revision surgery. The aesthetic or functional abnormalities that prompted revision surgery and the specific techniques used to correct them were explored as well.

METHODS

Patients with upper lip skin defects at least 3.0 cm² in area that were reconstructed with V-Y subcutaneous tissue pedicle advancement flaps were identified from the senior surgeon's (S.R.B.) prospective skin cancer reconstruction database. Inclusion criteria were at least 2 months of follow-up and cutaneous neoplasm as the cause of the defect. Defects with greater than 5-mm extension onto the cheek aesthetic unit (lateral to the melolabial fold) were excluded. All patients provided appropriate consent for preoperative, intraoperative, and postoperative photography, and this study received institutional review board approval from the University of Michigan. Variables extracted from patients' medical records included cause of the defect, sex, age, size of the defect, and depth of the defect (divided into skin, subcutaneous tissue, or involving the orbicularis oris muscle). Postoperative queries included presence or absence of flap necrosis, wound infection, wound dehiscence, and need for secondary procedures. Defects were measured after resection of the primary lesion and freshening of any post-Mohs wound margins, and before undermining, in all cases.

Our surgical technique is as follows. After confirmation of tumor-free margins, reconstruction was performed in the operating room under intravenous sedation and local anesthesia in all patients. The defect was measured and vertical and horizontal dimensions were recorded. The V-Y subcutaneous tissue pedicle advancement flap was then outlined with a surgical marker. The width of the flap was equal to the greatest height of the lip defect. The flap was designed so it was at least twice the length of the width of the flap and tapered into the labio-mental sulcus. For most defects with a diameter greater than 2 cm, the remainder of the lip subunit lateral to the medial border of the defect is excised. For very large defects, we find it helpful to excise a crescent of skin around the alar-facial sulcus and replace it with a portion of the flap. This allows the superior aspect of the melolabial scar line to lay in a natural position just lateral to the ala. This flap design prevents a transverse scar across the base of the peninsula of skin composing the alar-facial sulcus and prevents the abrupt termination of the melolabial fold at the alar base (**Figure 1**).

The skin and subcutaneous tissues were then infiltrated with a mixture of either 1% lidocaine with 1:100 000 dilution of epinephrine (small- to moderate-sized flaps) or a 1:1 mixture of 0.5% lidocaine and 0.25% bupivacaine with 1:200 000 dilution of epinephrine (large flaps) to avoid a local anesthetic toxic reaction. The face was then prepared and draped in the usual sterile fashion. All flap incisions were then made through the dermis. The distal flap was then undermined in the subcutaneous plane, while the medial border of the flap was sharply

dissected from the orbicularis oris muscle fibers. The proximal third of the flap was similarly elevated in the subcutaneous plane. Most important, the middle third of the flap must remain pedicled to the richly perfused subcutaneous tissue. The adjacent subcutaneous cheek tissue can be freed from the pedicle by dissecting deeply perpendicular to the skin along the lateral border of the cheek incision. Deep dissection stops at the zygomatic major fascia to avoid injuring the facial nerve fibers entering the deep aspect of the facial muscles. The flap mobility is periodically evaluated by advancing the flap toward the defect until the necessary reach is achieved. Once tension-free advancement is possible, the flap is secured to the medial aspect of the defect. The flap is conservatively trimmed as needed. Excised skin can potentially be used for full-thickness skin grafting as needed for adjacent defects. The incisions are then closed in 2 layers, and a compression dressing is applied to prevent hematoma formation beneath the flap (**Figure 2**).

RESULTS

From January 1, 1994, through December 31, 2011, we identified 30 patients fitting the inclusion criteria, with upper lip defects with a mean (range) area of 7.0 (3.0-14.0) cm² (median, 6.25 cm²). Eighteen patients (60%) were women. Age at the time of reconstruction ranged from 34 to 86 years. The malignancy was basal cell carcinoma in 16 cases, whereas the rest were atypical junctional melanocytic hyperplasia or melanoma in situ. There were no instances of wound dehiscence or partial flap loss. One patient received a course of oral antibiotics for skin erythema and presumed cellulitis that resolved without any adverse consequences. The defect involved the nasal ala in 4 cases and the vermilion in 3 cases. At least 1 revision surgery was performed in 14 of the 30 patients (47%). Four of these patients (13%) underwent a second revision, and 1 of these (3%) required a third revision. During these 19 revision surgical procedures, flap contouring (11 times) and Z-plasty (9 times) were the most commonly used techniques. Vermilionectomy, scar revision, and removal of a standing cutaneous deformity were each used 6 times. Vermilion advancement and skin excision were rarely used (twice each).

Logistic regression analysis was used to model defect depth (skin, into subcutaneous tissue, or into muscle), size (in square centimeters), vermilion involvement, and alar involvement in relation to revision surgery. Backward variable selection identified vermilion involvement as the only predictor of undergoing revision surgery. Because the R^2 (a measure of statistical power) for this model was only 0.2, regression was underpowered to detect whether vermilion involvement was a significant predictor of needing revision surgery. A 2-tailed t test to explore the hypothesis that increasing defect size would be a predictor of revision surgery showed that this was not the case ($P=.55$). Individual χ^2 analysis was then performed for each categorical independent defect variable (depth, alar involvement, and vermilion involvement). Vermilion involvement showed a trend toward significance ($P=.09$), whereas the other individual variables were clearly not significant. The Fisher exact test was used instead of the χ^2 test for analysis of alar and vermilion involvement because of small sample sizes. Defect involvement of

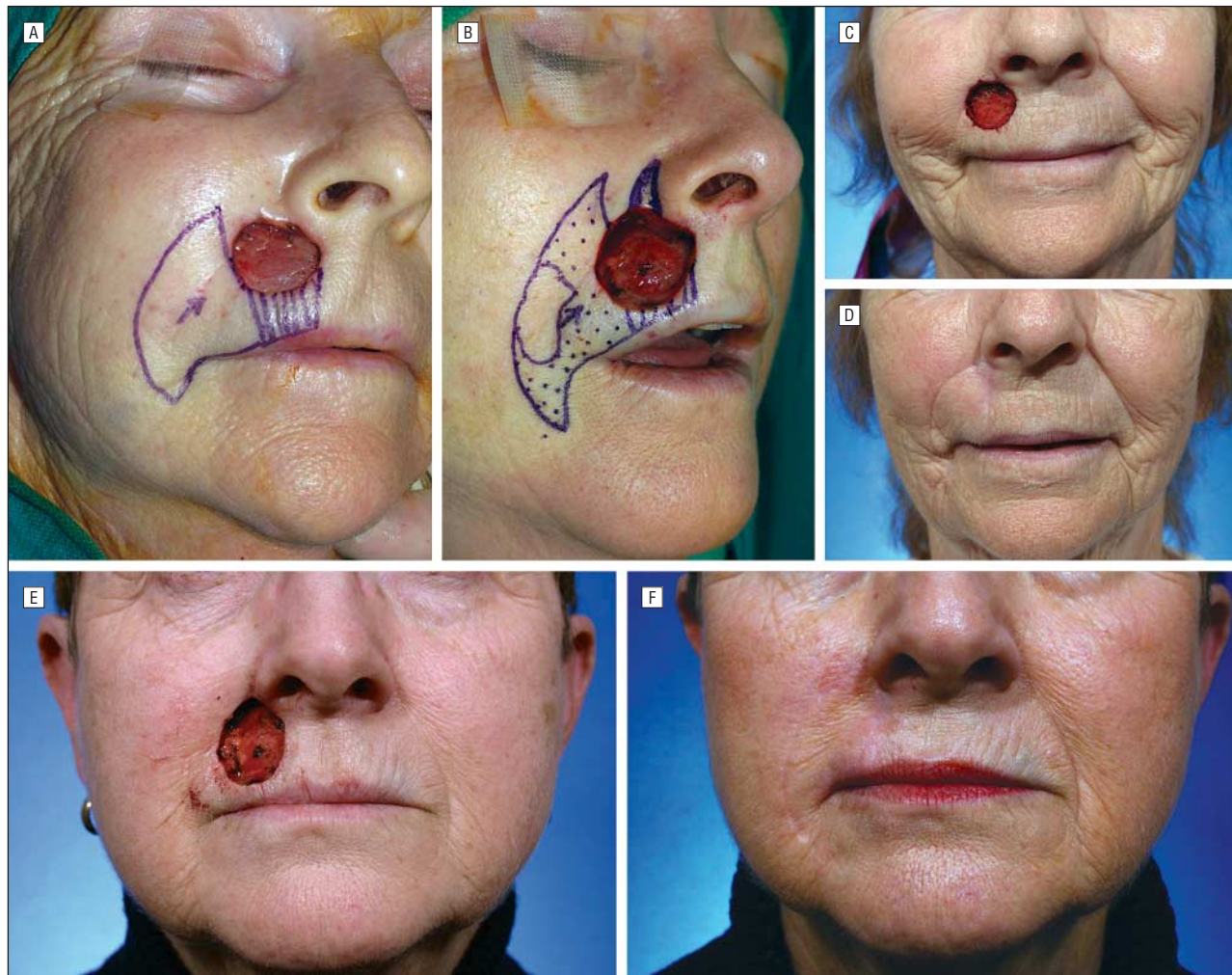


Figure 1. Comparison of 2 similar defects closed with slightly different techniques. A, Patient A (74 years old) with 2×2 -cm defect closed after removing the rest of the right lip subunit. B, Patient B (68 years old) with 2.5×3.5 -cm defect closed after removing the subunit *and* a perialar crescent. C and D, Patient A before and after reconstruction. The melolabial fold is quite asymmetric. E and F, Patient B before and after reconstruction. There is no noticeable asymmetry of the melolabial creases.

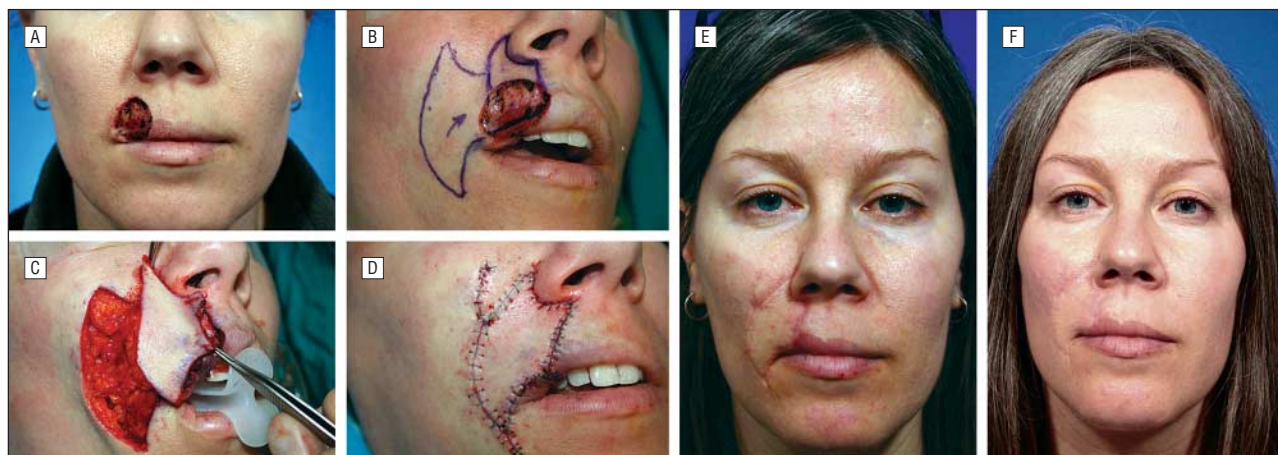

Figure 2. Surgical technique. A, 38-year-old woman with 3.0×1.7 -cm defect of the right upper lip with a significant vermilion component. B, Planned flap marked out as well as removal of the remainder of the right lip subunit inclusive of a perialar crescent. C, Flap raised, demonstrating subcutaneous tissue pedicle based on the middle third of the flap. D, Flap inset. E, Two months after flap inset. F, Eight months after 2 revisions that included contouring, scar revision, and Z-plasty.

the nasal ala *or* vermilion was found to increase the likelihood of undergoing revision surgery ($n=7$) (83% remission rate, $P=.03$). We then performed a 2-tailed *t*

test for just the subset of cases *without* alar or vermilion involvement, and defect size remained nonsignificant ($n=23$) (30% revision rate, $P=.68$).

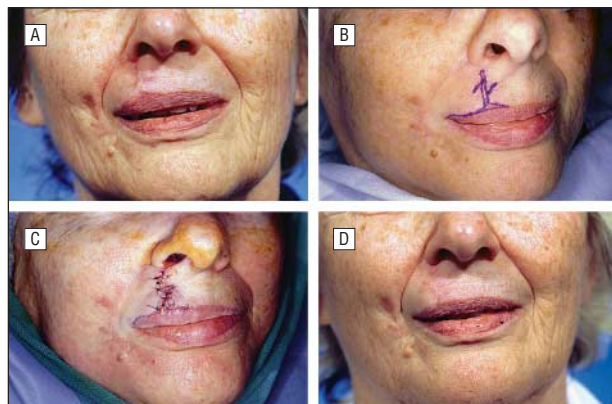

Figure 3. Typical causes for revision along the medial suture line. A, Widened vertical scar with shortening of the upper lip and elevation of the vermilion. B, Planned multiple Z-plasty, scar excision, and vermilionectomy. C, Immediately after revision. D, Six months after revision. Reprinted with permission from Baker SR. *Local Flaps in Facial Reconstruction*. St Louis, MO: Mosby Elsevier; 2007:732.

COMMENT

The V-Y subcutaneous tissue pedicle advancement flap has been previously described in upper lip reconstruction. To our knowledge, Zook et al³ in 1980 were the first to report using the V-Y island advancement flap for upper lip reconstruction following trauma or oncologic resection. In their version, the flap was not formally undermined but was gently “stretched” along its periphery to increase movement. This would limit the flap to smaller defects and would increase the chance of requiring flap contouring at a second stage. In 1990, Skouge⁴ presented an excellent discussion of the anatomy of the upper lip and reported 4 upper lip defects closed with V-Y subcutaneous tissue pedicle advancement flaps. That same year, Hurwitz⁵ described a technique that advanced both upper lip skin and vermilion to close defects involving the red lip. Carvalho et al⁶ later described modifications allowing reconstruction of full-thickness upper lip defects using V-Y flaps.

The V-Y subcutaneous tissue pedicle advancement flap is our preferred technique for closing most upper lip skin defects larger than 1 cm in diameter that are not midline, full thickness, or centered on the red lip. In a prior publication from our group,² large upper lip and medial cheek defects closed with this technique were associated with a 35% revision rate. The purpose of this report was to further investigate this statistic.

We found a 47% revision rate in this updated series that included cheek defects. Alar or vermilion involvement by the defect had a statistically significant association with revision surgery. The depth of the defect was not found to be important. Defect size alone, either including or excluding subjects with alar or vermilion involvement, was also not a significant factor ($P > .5$). Thus, our results suggest that even very large upper lip defects without alar or vermilion involvement can be reconstructed with good results in just 1 stage. This makes sense because V-Y subcutaneous tissue pedicle advancement flaps can resurface the entire hemilip. However, once a natural aesthetic boundary is crossed (onto the nose or

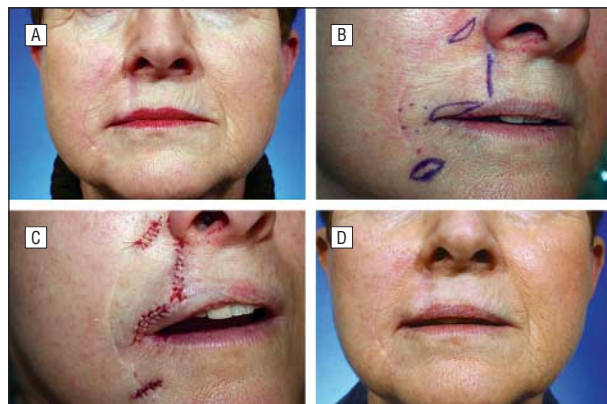

Figure 4. Typical causes for revision along the inferior suture line and trailing edge of the flap. A, Patient B (from Figure 1) 11 months following reconstruction. B, Planned excision of hypertrophic medial and melolabial scars, removal of excess skin along the lateral vermilion, and excision of a standing cutaneous deformity along the trailing edge of the flap on the chin. C, Immediately following excision. D, Ten months after revision.

lip), the likelihood of needing further refinement surgery increases. It should be emphasized that the island advancement flap is not used to reconstruct an adjacent alar defect. These are either left to heal by secondary intention if minimal, skin-grafted if appropriate, or reconstructed with a different flap. We typically close adjacent vermilion defects with a separate vermilion advancement flap, but the Hurwitz modification⁵ could be used as well.

In our series, 7 different revision techniques were necessary: flap contouring (debulking), Z-plasty, vermilionectomy, scar revision, removal of standing cutaneous deformity, vermilion advancement, and skin excision. Further analysis revealed certain patterns. With large lip defects, the medial flap border is often placed on significant wound closure tension, and as a consequence, the scar along the medial aspect of the flap frequently widens or thickens over time. Also, the red lip can become elevated from scar contracture at its junction with the flap’s medial border. A common and effective solution to this problem is to perform a multiple Z-plasty along the vertical axis of the scar with excision of the vermilion that has been elevated by scar contracture (**Figure 3**).

A second common problem area is along the lateral half of the vermilionocutaneous border. The distance between the melolabial crease and the red lip decreases as the crease descends from the nose toward the lateral commissure. When one is performing V-Y subcutaneous tissue pedicle advancement flaps for large lip defects, tissue can accumulate above and medial to the commissure, causing fullness and a depressed vermilion. This redundant tissue represents a standing cutaneous deformity that develops as the flap is advanced and to some degree pivoted toward the defect. We typically perform a skin excision from the inferior border of the flap along the vermilionocutaneous border and debulk the area of fullness through this opening before closing the skin. Sometimes vermilion advancement is required in addition to skin excision from the flap to optimize the vermilionocutaneous junction (**Figure 4**).

Last, a standing cutaneous deformity often forms along the flap’s trailing edge, where the “Y” is formed upon clo-

sure of the donor site. This problem is solved by excising a small ellipse of skin oriented along the axis of the relaxed skin tension lines (Figure 4).

To our knowledge, this is the first in-depth analysis of large upper lip defects closed with a V-Y subcutaneous tissue pedicle advancement flap. Reports such as this can help to counsel patients preoperatively about the likelihood of needing revision surgery. Large upper lip defects are relatively rare, and this information can serve as a resource when planning initial or revision surgery using this technique. Perhaps most important, by identifying the areas that most commonly require refinement, we hope to develop modifications of the initial procedure that can reduce the need for revision surgery.

In conclusion, partial-thickness defects of the upper lip at least 3.0 cm² in area that were reconstructed with a V-Y subcutaneous tissue pedicle advancement flap had a 47% revision rate. Alar or vermilion involvement by the defect was associated with an increased rate of revision surgery (86%). The areas that will require revision are predictable, and there are straightforward techniques to optimize the final result. Recognizing common problem areas might allow the surgeon to modify the primary surgery, thus reducing the revision rate.

Accepted for Publication: January 17, 2012.

Correspondence: Garrett R. Griffin, MD, Department of Otolaryngology–Head and Neck Surgery, University of Michigan Health System, 1904 Taubman Center, 1500

E Medical Center Dr, SPC 5312, Ann Arbor, MI 48109 (gargriff@med.umich.edu).

Author Contributions: *Study concept and design:* Griffin, Weber, and Baker. *Acquisition of data:* Griffin. *Analysis and interpretation of data:* Griffin. *Drafting of the manuscript:* Griffin and Weber. *Critical revision of the manuscript for important intellectual content:* Griffin, Weber, and Baker. *Statistical analysis:* Griffin. *Administrative, technical, and material support:* Weber. *Study supervision:* Weber and Baker.

Financial Disclosure: None reported.

Additional Contributions: We thank the University of Michigan Center for Statistical Consultation and Research for their assistance with statistical analysis.

REFERENCES

1. Baker SR. *Local Flaps in Facial Reconstruction*. St Louis, MO: Mosby Elsevier; 2007.
2. Rustad TJ, Hartshorn DO, Clevens RA, Johnson TM, Baker SR. The subcutaneous pedicle flap in melolabial reconstruction. *Arch Otolaryngol Head Neck Surg*. 1998;124(10):1163-1166.
3. Zook EG, Van Beek AL, Russell RC, Moore JB. V-Y advancement flap for facial defects. *Plast Reconstr Surg*. 1980;65(6):786-797.
4. Skouge JW. Upper lip repair—the subcutaneous island pedicle flap. *J Dermatol Surg Oncol*. 1990;16(1):63-68.
5. Hurwitz DJ. Composite upper lip repair with V-Y advancement flaps. *Plast Reconstr Surg*. 1990;85(1):120-122.
6. Carvalho LMY, Ramos RR, Santos IDAO, Brunstein F, Lima AH, Ferreira LM. V-Y advancement flap for the reconstruction of partial and full thickness defects of the upper lip. *Scand J Plast Reconstr Surg Hand Surg*. 2002;36(1):28-33.